

Types

Blunt trauma

Compression, secondary to a direct blow, or against a fixed external object (e.g. seatbelt), or from deceleration forces (e.g. fall). Liver & spleen most frequently damaged organs.

Penetrating trauma

Object breaching peritoneum, e.g. high velocity missile (e.g. GSW) or stab wound (e.g. knife).

Epidemiology

- 1.5M:1F
- Fall from height <5m & MVA most common causes.

Assessment

See Trauma Assessment for details.

History: Mechanism, AMPLE. Any major injury to adjacent cavities: chest or pelvis.

Examination:

- External evidence of trauma:
 - Bruising - e.g. seat belt sign, Cullen's sign (periumbilical → ?retroperitoneal injury)
 - Laceration. Entry/Exit wounds. Could trauma involve thoracic cavity?
- Tenderness, guarding.
- Serial exams for initially benign abdo. Abdo girth not useful.
- Sensory examination may reveal a spinal cord injury.

Investigations

Urine: Urinalysis ?blood

Bloods: FBC, UEC, LFT, BSL, amylase/lipase, G&H, β hCG, ABG if major trauma, \pm coags

Imaging: (Trauma series may have already been done). See FAST Scan/DPL article.

- CXR - ?free air under diaphragm if erect CXR, diaphragm hernia/rupture. Non-specific pleural effusion or elevated hemidiaphragm.
- FAST - investigation of choice if haemodynamically unstable. ?haemoperitoneum.
- CT scan - investigation of choice if haemodynamically stable.
 - Pros: Imaging retroperitoneal structures, TL-spine. May be done with other scans e.g. chest/pelvis. Often determines need for OT. Give IV contrast. PO contrast (not essential). Higher specificity for solid organ injury than FAST.
 - Cons: May miss hollow viscus, pancreatic or diaphragmatic injuries. Patient needs to be fairly stable. Contrast risks.
- Diagnostic peritoneal lavage (DPL) - Infrequently used now. If positive → laparotomy, but as non-specific re injury type fairly high non-therapeutic laparotomy rate.

Management Overview (See also Trauma Overview/Assessment)

- Resuscitation
- Analgesia
- Determine likely abdominal injuries & if penetrating or blunt
 - Antibiotics for penetrating trauma or suspected bowel blunt trauma
- Determine if haemodynamically stable or not
- Decision on management (OT, serial exams/inv, D/C) based on clinical signs & invs (FAST, DPL, CT) as below:

Blunt Trauma Algorithm

Most predictive positive LR for blunt abdo injury are rebound tenderness, a seat belt sign, ↓BP in ED, Hct < 30%, AST or ALT > 130, >25 RBCs in urine, base deficit < -6, and a +ve FAST.

However only base deficit and FAST have useful negative LRs of 0.12 and 0.26, respectively.

1. Is **immediate OT** indicated?

- Few reliable clinical signs
- Haemodynamic instability with isolated abdominal injury
- Persistent peritonitis
- Pneumoperitoneum/diaphragmatic rupture on CXR
- Significant & persistent GI haemorrhage in NGT/vomitus.

2. Is patient haemodynamically **stable**?

- Yes:
 - Is patient alert and has **no** abdominal tenderness/pain
 - Yes: **Observe with serial examinations**
 - No: CT (can do FAST as well, but will need CT)
 - Normal CT/Non-op injury: **Observe with serial examinations**
 - Operative injury: **OT**
- No:
 - Any intraperitoneal blood on FAST or DPL (best if SB injury suspected)
 - Yes: **OT**
 - No: Resus & CT when stable
 - Normal CT/Non-op injury: **Observe with serial examinations**
 - Operative injury: **OT**

Penetrating Trauma (Anterior Abdomen) Algorithm

1. Is **immediate OT** indicated?

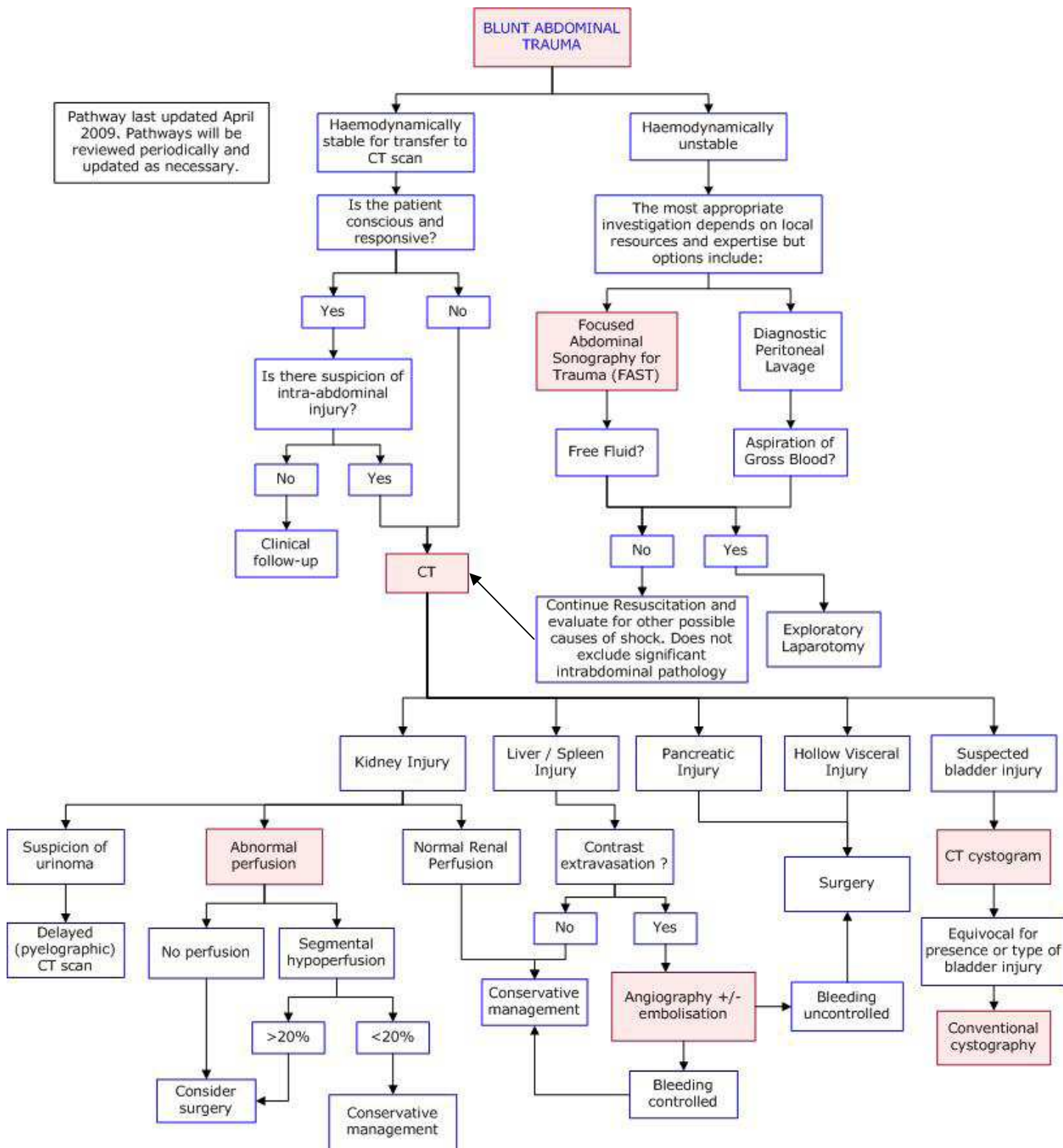
- Haemodynamically unstable (do FAST to check for pericardial effusion)
- Peritoneal irritation
- Evisceration
- Diaphragmatic injury
- Gastrointestinal haemorrhage
- Implement in situ
- Intraperitoneal air
- Gunshot wound
- Unreliable clinical exam (↓LOC, intubated)

2. Has **peritoneum** been **breached**? Determined by: Local wound exploration (for anterior abdo wounds only), free intraperitoneal air on CXR (or CT if already done), or laparoscopy (FAST less sensitive as these patients are stable):

- Yes or unsure:
 - Is there an injury? Determined on triple contrast CT or laparoscopy (DPL no longer in common use),
 - Yes: **OT** in most cases
 - No: **Observe with serial examinations**
- No: Local wound management, observe or **discharge** if no other injuries.

Full Blunt Abdominal Trauma Imaging Algorithm

Pathway last updated April 2009. Pathways will be reviewed periodically and updated as necessary.



Splenic Trauma

Overview

- Most commonly injured organ in blunt trauma.
- Delayed rupture possible at 2-14d post injury.

Assessment

- More commonly with LUQ or lateral impact as well as major ant/post trauma.
- LUQ pain, tenderness or guarding common
- Left shoulder tip/scapular referred pain
- Haemodynamic instability
- Risk factors: Recent EBV, malaria, splenomegaly from other causes. Lower L rib #s.

Investigations

See above.

NB: FAST if unstable. CT >95% sensitive in stable patient. CXR/AXR non specific - may see raised left hemidiaphragm, soft tissue mass, or obscuration of psoas shadow. DPL may be -ve if contained haematoma.

Injury Grading

Several grading systems.

Grade	Injury Type/Description
I	Hematoma: subcapsular, non-expanding, <10% surface area. Laceration: capsular tear, non-bleeding, <1cm parenchymal depth.
II	Hematoma: subcapsular, non-expanding, 10-50% SA, intraparenchymal, non-expanding <5cm in diam. Laceration: capsular tear, active bleeding, 1-3cm parenchymal depth, not involving trabecular vessel.
III	Hematoma: subcapsular, >50% surface area or expanding, ruptured subcapsular haematoma with active bleeding, intraparenchymal hematoma >5cm or expanding. Laceration: >3cm parenchymal depth or involving trabecular vessel.
IV	Hematoma: ruptured intraparenchymal hematoma with active bleeding. Laceration: involving segmental or hilar vessels with major (>25%) splenic devascularization.
V	Laceration: completely shattered spleen. Vascular: hilar vascular injury that devascularizes spleen.

Management

General Trauma Mx.

Specific:

- Fluid resuscitation - 20% req blood.
- Angiography/embolisation if arterial bleeding
- Surgery: Non-operative Mx common for Grades I & II, sometimes for III. OT more likely if III, IV, other abdominal injuries, haemodynamically unstable, failure of conservative Mx. Splenorrhaphy, partial or total splenectomy possible.
- If splenectomy - Hib, Pneumococcal & meningococcal ± influenza vacs, early ABx for febrile illness, ± prophylactic penicillin (children yes, adults controversial).

Hepatic Trauma

Overview

- Commonly seen with splenic injury
- Most commonly injured organ in penetrating trauma
- Difficult to repair
- High incidence of stress ulcers

Assessment

- RUQ pain, tenderness or guarding may not be marked
- Right shoulder tip/scapular referred pain
- Haemodynamic instability
- Lower R rib #s.

Investigations

See above.

NB: FAST if unstable. CT >95% sensitive in stable patient. CXR/AXR non specific - may see raised left hemidiaphragm, soft tissue mass, or obscuration of psoas shadow. DPL may be -ve if contained haematoma.

In children abnormal LFTs → 90% sensitive for injury (in adults too non-specific). In either normal LFTs do not exclude injury.

Injury Grading

Grade	Injury Type/Description
I	Hematoma: subcapsular, non-expanding, <10% surface area. Laceration: capsular tear, non-bleeding, <1cm parenchymal depth.
II	Hematoma: subcapsular, non-expanding, 10-50% SA, intraparenchymal, non-expanding <10cm in diam. Laceration: capsular tear, active bleeding, 1-3cm parenchymal depth, <10cm in length.
III	Hematoma: subcapsular, >50% surface area or expanding, ruptured subcapsular haematoma with active bleeding, intraparenchymal hematoma > 10cm or expanding. Laceration: >3cm parenchymal depth
IV	Hematoma: ruptured intraparenchymal hematoma with active bleeding. Laceration: parenchymal disruption of 25-75% of 1 hepatic lobe or 1-3 Couinaud segments in 1 lobe.
V	Laceration: parenchymal disruption involving >75% of hepatic lobe or >3 Couinaud segments in 1 lobe. Vascular: juxtahepatic venous injuries (central major hepatic veins, retrohepatic vena cava.)
VI	Vascular: hepatic avulsion.

Management

General Trauma Mx.

Specific:

- Ensure Rx of coagulopathy & hypovolaemia (blood products often req).
- Angiography/embolisation if arterial bleeding
- Surgery: Usually for Grade IV and above. Initially perihepatic packing for haemorrhage control until more stable then definitive repair.

Prognosis

Mortality from liver injury: III (7%), IV (30%), V (65%), VI (~100%)

Bowel Trauma

Overview

- Associated with blunt trauma compression injuries e.g. seat belt.
- 5% blunt abdo trauma
- Seat belt sign
- Free gas on Erect CXR or CT.

Mesenteric Injury

- Haematoma or vascular laceration
- CT + contrast is sensitive and usually determines need for OT.
- If bleeding → repair. Haematomas usually do not require specific therapy
- Supportive Mx for ileus.

Duodenal Injuries

- Penetrating > blunt but later usually more serious. Mortality 10% vs 15%
- Assoc with seat belt.
- May include bile duct injury.
- Free gas under diaphragm or in biliary tree.
- Inv: NG/PO contrast aids CT
- Mx: OT if free perforation.

Small Bowel Injury

- 3% of abdominal trauma
- Often associated with other injuries e.g. mesenteric haematoma or Chance fracture.
- Mortality rate if a SB injury = 20%
- Main be difficult to diagnose as often delayed pain/peritonism.
- Inv: Single erect CXR only 25% sensitive, CT only 40% sensitive, but DPL >95% sensitive
- Mx: Drip & suck, primary repair.

Large Bowel Injuries

- Mortality ~10%
- Grading:

Grade	Injury Type/Description
I	Contusion, partial thickness lac
II	Lac <50% of bowel circumference
III	Lac >50% of bowel circumference
IV	Transection
V	Transection with tissue loss or devascularisation of bowel segment

- OT for Grade II-V - primary repair+anastomosis or, if contamination/shock/major injury, colostomy.

Ureteric Trauma

- Rare. Usually post GSW.
- Haematuria absent in 25%
- Contrast CT or retrograde urethrogram required.
- Similar grades to urethra trauma
- Surgery + urinary stenting.

Renal Trauma

Overview

- Kidney most frequently injured urologic organ
- 75% blunt trauma
- Diagnosis sometimes delayed by waiting for urinalysis

Assessment

- Microscopic haematuria: Warrants further inv if:
 - Penetrating trauma
 - Hypotensive
 - Child with >50RBC/hpf
- Macroscopic haematuria/haem unstable/loin tenderness or rigidity: Always inv.
- CT+contrast: inv of choice. MRI/IVP alternatives. USS not as sensitive.

Injury Grading

Grade	Injury Type/Description
I	Haematuria+normal urologic studies or Small non-expanding subcapsular haematoma If bilateral → Grade II
II	Haematoma confined to retroperitoneum or Lac<1cm deep without urinary extravasation If bilateral → Grade III
III	Lac>1cm deep without urinary extravasation If bilateral → Grade III
IV	Deep lacerations or Renovascular injury with contained haematoma
V	Renal fracture or Avulsion/devascularised kidney

Management

Grade I-III - non-operative usually.

Grade IV & V- Usually OT. 10% (IV) & 85% (V) chance of nephrectomy

Bladder Trauma

Overview

- ~80% have assoc pelvic #

Assessment

- Suprapubic tenderness/rigidity
- Difficulty voiding

Investigation

- Macroscopic haematuria (>95%)
- CT cystogram or conventional cystography (≥300ml contrast) looking for extravasation.

Injury Grading:

Grade	Injury Type/Description
I	Intramural haematoma or partial thickness lac
II	Extraperitoneal bladder wall lac<2cm
III	Extraperitoneal bladder wall lac>2cm or intraperitoneal bladder wall lac<2cm
IV	Intraperitoneal bladder wall lac>2cm
V	Extraperitoneal or intraperitoneal bladder wall lac extending in to bladder neck or trigone

Management

- Transurethral catheter is preferred if possible to SPC.
- Surgical repair. Urgent if intraperitoneal portion of bladder involved.

Urethral Trauma

Overview

- >Blunt trauma more common in males usually below urogenital diaphragm

Assessment

- 50% have no initial signs
- Blood at penile meatus, perineal collection/scrotal haematoma.
- High riding prostate
- In absence of straddle injury and pelvic # unlikely to have blunt trauma injury.
- In penetrating trauma: injury excluded if no blood at meatus/normal micturition or easy IDC placement/no RBC on UA.

Investigation

- Retrograde urethrogram prior to attempted catheterisation

Injury Grading:

Grade	Injury Type/Description
I	Contusion or blood at meatus with normal urethrogram
II	Stretch injury - elongation without extravasation on urethrogram
III	Partial disruption
IV	Complete disruption <2cm separation
V	Complete disruption <2cm separation or extension of lac in to prostate or vagina

Management

- Minor defect: gentle expert urethral catheterisation.
- Major defect: SPC + delayed urethroplasty.

Other Retroperitoneal Trauma

Pancreatic Injuries

- Similar to duodenal injuries
- Inv: CT sensitivity ~50%, Amylase/lipase early false +ve. Amylase 35% sens, PPV 1.5%.
- Mx: Penetrating: ERCP+surgical repair. Blunt: as for pancreatitis.

Adrenal Haemorrhage

- Up to 5% in blunt trauma.
- 95% unilateral, 80% right sided.
- Found on CT scan.
- Mx: Occ embolisation req for ongoing haemorrhage. Corticosteroids if Addison's occurs.

Abdominal Vascular Injuries

- Very rare. Likely to be fatal if major artery involved.

Scrotal Trauma

- Testicular rupture rare in blunt trauma, more common in penetrating trauma.
- Inv: USS but may underestimate injury.
- Intratesticular haematoma → pain+.
- Mx: Supportive - ice, elevation, analgesia.
- Surgery Required if penetrating trauma or testicular haematoma (high incidence of infection/necrosis). Often done any way as USS not sensitive enough to rule out injury.