

## Epidemiology

- ~5% of ED presentations

## Causes

ORGAN SYSTEM	CRITICAL DIAGNOSES	EMERGENT DIAGNOSES	NONEMERGENT DIAGNOSES
Cardiovascular	Acute myocardial infarction Acute coronary ischemia Aortic dissection Cardiac tamponade	Unstable angina Coronary spasm Prinzmetal's angina Cocaine-induced pericarditis or myocarditis	Valvular heart disease Aortic stenosis Mitral valve prolapse Hypertrophic cardiomyopathy
Pulmonary	Pulmonary embolus Tension pneumothorax	Pneumothorax Mediastinitis	Pneumonia Pleuritis Tumor Pneumomediastinum
Gastrointestinal	Esophageal rupture (Boerhaave)	Esophageal tear (Mallory-Weiss) Cholecystitis Pancreatitis	Esophageal spasm Esophageal reflux Peptic ulcer Biliary colic
Musculoskeletal			Muscle strain Rib fracture Arthritis Tumor Costochondritis Nonspecific chest wall pain
Neurologic			Spinal root compression Thoracic outlet Herpes zoster Postherpetic neuralgia
Other			Psychologic Hyperventilation

## Assessment

### History

- Pain
  - Position - central versus left/right sided
  - Quality & severity - visceral (dull, poorly located) vs somatic (sharp, located, pleuritic). Not sensitive to rule out any Dx. Pleuritic CP makes ACS less likely.
  - Radiation - to neck, jaw, shoulders or arms - common in ACS, to back classically in aortic dissection
  - Assoc symptoms - SOB (PE, ACS, pneumonia), N&V, diaphoresis, cough
  - Time course - onset, duration (AMI usually >10mins), change over time
  - Precipitants/Relievers
    - ?Assoc with exertion (ACS), Forceful vomiting (oesophageal rupture), Trauma (PTX, tamponade), Fever & cough (pneumonia/pleurisy), Pain changes on lying down (pericarditis) or movement (MSK), Meals (GI causes)
  - Previous episodes
- Treatment so far
- Allergies & Medication
- Past Medical Hx - IHD, thromboembolic disease, Ca, pregnancy
- Risk factors for conditions
  - IHD: FHx, HT, DM, smoking, hypercholesterolaemia (??use in acute situation), etc
  - PE: immobilisation, cancer, pregnancy/exogenous oestrogen, FHx/PMHx of PE/DVT
  - Aortic dissection: HT, Marfan's syndrome, coarctation, bicuspid AV, PMHx aortic instrumentation, pregnancy, atherosclerosis, smoking

- Oesophageal pain: GORD, PMHx achalasia or other motility disorder
- Pericarditis/Myocarditis: viral infection, RhF, recent MI or cardiac surgery, Ca, RadioRx, uremia, drugs
- Social Hx: smoking, drug abuse, employment, home situation, exercise tolerance

### *Examination*

- Limited usefulness as findings generally not specific to a single Dx
- Vital signs - none very specific.
  - Fever (pneumonia, other infective/inflammatory conditions, PE)
  - Hypoxia (PTX, pneumonia, PE)
  - Tachypnoea, tachycardia very non-specific (but they occur in 92% & 44% of PE)
  - HT > 160mmHg (dissection - but may also have ↓BP from tamponade or exsanguination)
- CVS
  - New murmur - PSM/ESM or midsystolic added sound (MVP)
  - Widely split S2 with loud P2 (large PE)
  - Muffled heart sounds, raised JVP, ↓BP, pulsus paradoxus (cardiac tamponade)
  - Radio-radial or radio-femoral delay or unequal upper limb BP suggests aortic dissection (uncommon finding)
  - Pericardial friction rub (pericarditis)
  - Hamman's sign (crunch on cardiac systole auscultation)
- Resp
  - Hyper-resonance, ↓breath sounds, tracheal shift, shock/hypoxia (tension PTX)
  - Localised chest wall tenderness: common in costochondritis, but doesn't exclude ACS, PE
  - Localised bronchial breathing (pneumonia)
  - Pleural rub (pleurisy)
- Abdo
  - Abdominal tenderness - may indicate GI disorder
- Other
  - Presence of DVT (40% of PEs, but not all are clinically apparent)
  - Neuro focal signs: aortic dissection

### *Investigations: (most important and discriminating are ECG & CXR)*

#### Bedside:

- ECG:
  - ↑ST - STEMI, pericarditis (also look for ↓PR), Aortic dissection may also have ischaemic looking ECG.
  - ↓ST - NSTEMI/ACS
  - ↓T - Wellens' LAD (deep or biphasic T in V<sub>2-3</sub>), PE (inf & ant ↓T. May also have sinus tachy, new RBBB, S<sub>I</sub>Q<sub>III</sub>T<sub>III</sub>)
  - Small amplitude complexes (tamponade, pericardial effusion)
- BSL - ?DM
- FAST - Pericardial effusion, PTX

## Lab:

- Haem: FBC (infection), D-Dimer (may be approp to r/o PE, aortic dissection). Coags.
- Biochem: cardiac markers (ACS), ABG, LFTs (cholecystitis), lipase (pancreatitis). Base line UEC.
- Micro: Bld cultures (if highly febrile), sputum sample (rarely useful), pleural fluid analysis

## Imaging:

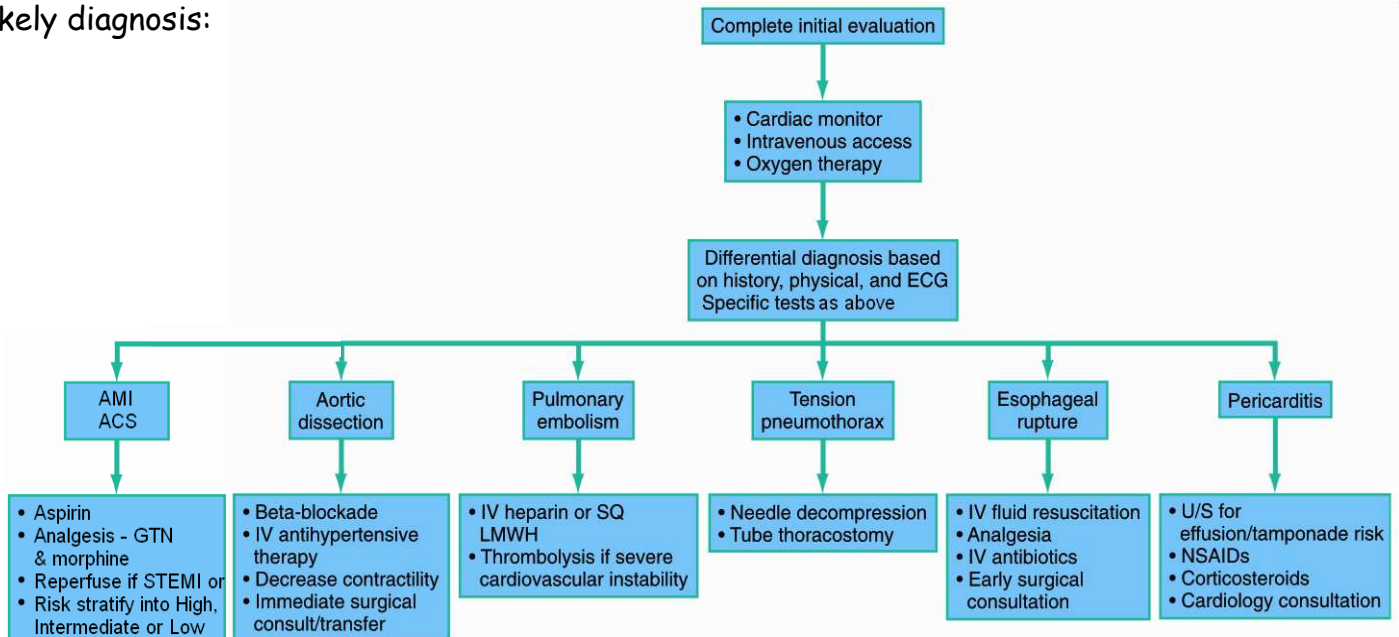
- CXR:
  - PTX
  - Consolidation/collapse (pneumonia)
  - CTR, upper lobe diversion, interstitial oedema (CCF)
  - Wedge-shaped pleural-based infiltrate, ↑hemidiaphragm, prominent pulmonary vasculature (PE)
  - Widened mediastinum, apical cap, ↓left mainstem bronchus, deviation of oesophagus, indistinct aortic knob, etc (aortic dissection)
- CT - CTPA (PE), CT aortography (dissection)
- VQ Scan - if normal CXR and CTPA **CI**
- USS: TT or TO Echo (ACS, pericarditis, tamponade, dissection), leg Doppler (DVT/PE)

## Initial management

### Resus

- If significantly abnormal vital signs or critical diagnosis suspected triage to resus and attach full non-invasive monitoring
- A/B:
  - If shocked+absent breath sounds - immed needle decompression of tension PTX
  - Apply high flow O2 if hypoxic or shocked
- C: IV access

*Specific:* See flowchart for critical Dx, otherwise complete investigations and treat based on likely diagnosis:



*Supportive:* Fluids, antibiotics, glycaemic control, temp control, O2, pain control, electrolyte balance, notes, IDC, NG, gastric protection and social support as indicated.

## Disposition:

D/C, ICU, HDU, CCU, Ward or D/C depending on condition and severity. Appropriate f/u.