

Gastrointestinal Examination

Prepare patient

- Introduction
- Position supine on single pillow exposing mid-chest to symphysis pubis

General Inspection

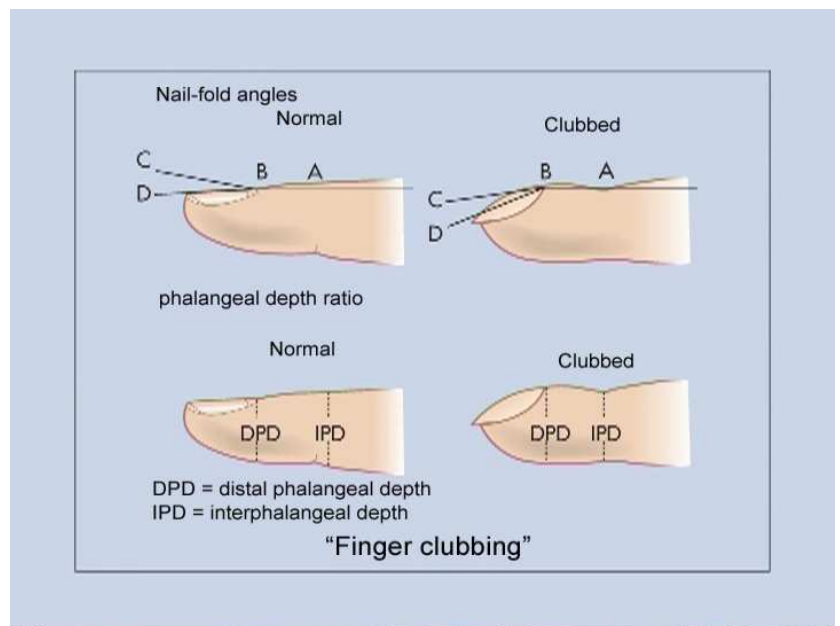
General signs:

- Wasting, jaundice (liver disease)
- Pigmentation (haemochromatosis, Addison's, Peutz-Jeghers)
- Bruising (liver disease)
- Scratch marks (chronic cholestasis)
- Mental state/drowsiness (encephalopathy)

Hands & Wrist

Clubbing (many causes including):

- Cyanotic congenital heart disease
- Infective endocarditis
- Atrial myxoma
- Lung Ca
- Chronic lung suppuration
 - Lung abscess or empyema
 - Bronchiectasis or CF
- Idiopathic pulmonary fibrosis
- Pleural mesothelioma
- Asbestosis
- **IBD**
- **Cirrhosis**
- **Coeliac disease**
- **SB lymphoma**
- Thyrotoxicosis (acropachy)
- Idiopathic/familial
- Rarely:
 - Pregnancy
 - 2° Hyperparathyroidism



Leuconychia - white opacification of nailbed (chronic liver disease)

Palmar erythema (liver disease, also thyrotoxicosis, pregnancy, RA, polycythaemia, idiopathic)

Dupuytren's contracture (alcoholism, manual workers, familial)

Anaemia (blood loss, malabsorption)

Asterixis - *hepatic flap* (extend wrists with spread fingers for 15s, also in HF, RF, Resp failure)

Face

Eyes: Jaundice, anaemia, kayser-Fleischer rings, xanthelasma

Mouth: fetor hepaticus, stomatitis, pigmentation, ulcers, telangectasia, gingivitis, glossitis, leucoplakia, candida

Salivary glands

Neck

Lymphadenopathy - cervical, auricular, occipital, supraclavicular & axillary lymph nodes

- Troisier's sign - large left supraclavicular LN + Ca stomach

Chest

Gynaecomastia

Spider naevi - SVC distribution - so arms & neck too

Body hair

Abdomen

Inspect:

- Scars
- Distension
 - Fat, fluid, faeces, flatus, foetus, fibroids/other tumours
- Localised masses (ask patient to breath deeply)
- Prominent veins - caput Medusae (portal ↑BP: flow below umbilicus is → legs) or IVC obstruction (flow below umbilicus is → heart)
- Striae (pregnancy, ascites, obesity, Cushing's syndrome)
- Bruising, Cullen's/Grey-Turner's, pigmentation
- Visible peristalsis (intestinal or pyloric obstruction)

Palpate: (Ask if sore anywhere)

Superficial

- Tenderness, mass outline
- If tender: ?guarding/rebound
- Deep
 - Organomegaly
 - Liver
 - Spleen
 - Kidneys
 - Also bladder, bowel (faeces)
 - Abnormal mass
- GB
 - Murphy's sign
 - Courvoisier's Law - Gallstones unlikely to be cause of enlarged GB if jaundiced
- ?Abdominal aortic aneurysm
- Inguinal lymphadenopathy & herniae
- Scrotum - testes
- Rectal exam - skin tags, haemorrhoids, prolapse, fissure, warts, fistula, prostate, tone, stool/blood

Percuss:

- Liver span (<13cm) & spleen
- Ascites - shifting dullness

Auscultate:

- Bowel sounds
- Vascular - Liver hum, renal artery bruits

Legs

Oedema, bruising (liver disease)

Other

Urinalysis, BP, temperature. Cardiac exam if enlarged liver.

